


# Skin manifestations in children with inborn errors of immunity in a tertiary care hospital in Iran

Zahra Salehi Shahrababaki MD<sup>1</sup> | Zahra Chavoshzadeh MD<sup>1</sup> |  
 Fahimeh Abdollahimajd MD<sup>2,3</sup> | Samin sharafian MD<sup>1</sup> |  
 Mahnaz Jamee MD<sup>4</sup> | Anastasia Bondarenko MD<sup>5</sup> | Tolve Mahdavi MD<sup>6</sup> 

<sup>1</sup>Immunology and Allergy Department, Mofid Children's Hospital, Shahid Beheshti University of Medical Sciences, Tehran, Iran

<sup>2</sup>Skin Research Center, Shahid Beheshti University of Medical Sciences, Tehran, Iran

<sup>3</sup>Clinical Research Development Unit of Shohada-e Tajrish Hospital, Shahid Beheshti University of Medical Sciences, Tehran, Iran

<sup>4</sup>Pediatric Nephrology Research Center, Research Institute for Children's Health, Shahid Beheshti University of Medical Sciences, Tehran, Iran

<sup>5</sup>Department of Pediatrics, Immunology, Infectious and Rare Diseases, European Medic School, International European Kyiv, Kyiv, Ukraine

<sup>6</sup>Department of Allergy and Clinical Immunology, Hazrat Rasoul Hospital, Iran University of Medical Sciences, Tehran, Iran

## Correspondence

Tolve Mahdavi, Department of Allergy and Clinical Immunology, Hazrat Rasoul Hospital, Iran University of Medical Sciences, Tehran, Iran.  
 Email: [tolve.mahdavi@gmail.com](mailto:tolve.mahdavi@gmail.com)

## Abstract

**Objectives:** Inborn errors of immunity (IEIs) are monogenic diseases of the immune system. Despite the increasing genetic advancements, the diagnosis of IEIs still lean on clinical diagnosis. Dermatological manifestations are observed in a large number of IEI patients and can lead to proper approach and prompt intervention.

**Methods:** This cross-sectional study was carried out between 2018 and 2020 on IEIs at a Children's tertiary care center in Tehran, Iran. Demographic details and age at onset of symptoms of IEI were recorded.

**Results:** Overall, 212 patients were included. Cutaneous findings were reported in 95 (44.8%) patients, and 61 of 95 (64.2%) reported skin lesions as the first clinical presentation. Skin infection (69, 72.6%) was the most frequent cutaneous manifestation, followed by eczematous rash (24, 25%).

**Conclusions:** Skin manifestations are a common feature in IEI patients and are readily recognizable by healthcare providers. This study tried to provide information on prognostic consequences.

## KEYWORDS

cutaneous manifestations, eczema, inborn errors of immunity, primary immunodeficiency diseases, skin infection

## 1 | INTRODUCTION

Inborn Errors of Immunity (IEIs) are a group of heterogeneous genetic disorders affecting development and function of the immune system.<sup>1</sup> These defects may lead to increased susceptibility to infectious, autoinflammatory, autoimmune, allergic, and neoplastic manifestations.<sup>2-4</sup> Today, more than 400 distinct disorders with IEI are recognized and, with technical advancements in next-generation sequencing, the number is growing rapidly.<sup>5,6</sup>

Inborn Errors of Immunity (IEIs) present with highly variable clinical presentations, among which cutaneous involvement is relatively common and occur in nearly 40% of patients with IEI over a lifetime of the disease course.<sup>7,8</sup>

The spectrum of skin manifestations in IEI children is quite broad and categorized as infectious, eczematous, pigment alteration, and autoimmune.<sup>8,9</sup> Skin involvement may be the predominant or initial symptom in specific IEIs and provide a clue for early detection of IEI, helping with timely selection of appropriate treatment and improving the prognosis.<sup>10</sup>

This is an open access article under the terms of the [Creative Commons Attribution-NonCommercial](https://creativecommons.org/licenses/by-nc/4.0/) License, which permits use, distribution and reproduction in any medium, provided the original work is properly cited and is not used for commercial purposes.

© 2023 The Authors. *Journal of Cutaneous Immunology and Allergy* published by John Wiley & Sons Australia, Ltd on behalf of The Japanese Society for Cutaneous Immunology and Allergy.

The dermatological manifestations in IELs are described in several studies<sup>7,8,11,12</sup>; however, the pattern of skin involvement in distinct IELs remains to be elucidated.

This study aimed to describe the diversity of cutaneous findings in children with different types of IELs to help primary physicians and dermatologists make an early diagnosis and accelerate prompt treatment and better outcomes.

## 2 | MATERIAL AND METHODS

This single-center cross-sectional study was carried out at Mofid Children's Hospital, Tehran, Iran. Data were retrospectively collected between 2018 and 2020 from 212 patients with IELs. The diagnosis of the immunodeficiency was based on the diagnostic criteria of the International Union of Immunological Societies (IUIS).<sup>13</sup> Secondary immunodeficiencies were excluded from the study.

Demographic data (including age, gender, and parental consanguinity, age at onset of symptoms, family history of IEL) and clinical details of skin disorders were recorded.

The diagnosis of skin manifestations was mostly made clinically and in certain circumstances skin biopsies were taken and examined by histopathologists for the confirmation of the diagnosis.

Statistical analyses were performed using the SPSS software version 26.0 (IBM Corporation).

## 3 | RESULT

A total of 212 patients with a definite diagnosis of IEL were enrolled in the study.

The median (IQR) age at onset of symptoms was 0.7 (0.08–2.0) years. Parental consanguinity was reported in 56 (58.9%) patients. Positive family history of IEL was identified in 21 (9.9%) patients.

Overall, 95 patients (44.8%) presented cutaneous manifestations during the course of the disease and 61 of 95 (64.2%) reported skin lesions as the first clinical presentation. Thirty (30.6%) patients were affected by more than one skin complications.

Table 1 shows the frequency of skin manifestations in children with IEL according to IUIS categories. Immunodeficiencies affecting cellular and humoral immunity was the main IEL (68, 32%), followed by congenital defects of phagocyte number, function, or both (57, 26.8%), predominantly antibody deficiencies (37, 17.4%), combined immunodeficiency (CID) with associated or syndromic features (24, 11.3%), diseases of immune dysregulation (18, 8.4%), complement deficiencies (11, 5.11%), defects in intrinsic and innate immunity (7, 3.3%), and auto-inflammatory disorders (1, 0.4%).

In our study, skin manifestation revealed the diagnosis of IEL in 26.5% of patients. Skin infection (69, 72.6%) was the most common cutaneous involvement followed by eczema (24, 25%), pigment alterations (7, 7.4%) erythroderma (5, 5.3%), autoimmune/vasculitis (5, 5.3%) and granuloma (1, 1.1%). Among infectious lesions, bacterial

infections (48, 69.5%) were the main cause of infection, followed by fungal (13, 18.8%) and viral infections (8, 11.5%).

Chart 1 shows the distribution of skin manifestations according to specific categories of IEL.

As illustrated in Figure 1, the most common skin disorder in all groups of IELs was infectious and patients with CID manifested the most diverse cutaneous manifestations. Some interesting features of cutaneous findings in our immunodeficient patients are exhibited in Figures 2 to 7.

## 4 | DISCUSSION

Inborn Errors of Immunity (IEIs), formerly referred to as primary immunodeficiency disorders (PID), are genetic defects in the immune response that have a wide clinical spectrum.<sup>14</sup> Skin manifestations are common findings among several IEL and can provide a unique clinical picture, attention to which can provide early diagnosis of patients with IEL, leading to better prognosis and quality of life.<sup>15</sup> Of note, cutaneous manifestations in IELs are not pathognomonic for a specific immunodeficiency and can be present even in patients with normal immune system. Therefore, the clinical approach to IEL patients with skin involvement should be considered in the background of the natural history of their disease. In light of this, the present study aimed to highlight demographic/clinical data regarding the distribution of skin disorders among distinct types of IEL to general practitioner/ pediatricians to further facilitate the identification of IEL in children with cutaneous involvement.<sup>7</sup>

In this study, almost half of the study population (95, 44.8%) presented with some type of cutaneous involvement as initial manifestation. In the literature, there are few studies on skin manifestations in pediatric IEL. In a study which included 313 children with IEL in Kuwait, 40.3% presented with dermatological symptoms as preliminary manifestation.<sup>8</sup> In another retrospective single center Iranian study, skin complication was reported in 46.2% of patients, including dermatitis, psoriasis, eczema, and vitiligo.<sup>16</sup> According to Dhoubi et al.,<sup>11</sup> cutaneous involvement was the presenting feature in 24.5% of all patients with IE which is much lower than this study (67.4%). It seems that a multidisciplinary approach composed of dermatologists and immunologists can govern early identification of affected individuals.

In the study population, cutaneous infections were the most common skin findings. Bacteria were the leading cause of infection in 48 (69.5%) patients, followed by fungal 13 (18.8%) and viral 8 (11.5%) pathogens. In the present study, skin infections were significantly more frequently seen in patients with Congenital defects of phagocyte number or function as compared to other groups of IEL. In a retrospective observational study conducted by López-Quintero et al on 306 patients, the prevalence of cutaneous infections was 56.6%; in which 18 children (21.7%) had bacterial infections.<sup>7</sup>

Eczema was by far the second most common cutaneous manifestation in 24 (25%) patients with IELs. An IEL should also be assumed when a patient shows severe atypical refractory to therapy,

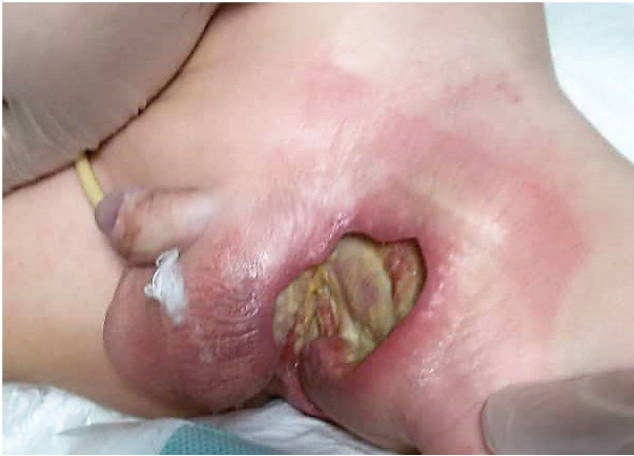TABLE 1 Frequency of skin manifestations in children with IEI according to IUIS classification.

IEI category	Total number of patients (n, %)	Patients with skin manifestation (n, %)
Immunodeficiencies affecting cellular and humoral immunity	68 (32%)	31 (45%)
(a) SCID	18 (8.4%)	10 (55%)
(b) Combined immunodeficiencies generally, less profound than SCID	50 (23.5%)	21 (42%)
CID with associated or syndromic features	24 (11.3%)	9 (37.5%)
(a) WAS	3 (1.4%)	3 (100%)
(b) AT	10 (4.7%)	2 (20%)
(c) ICF1	3 (1.4%)	0
(d) AD-HIES (Job sd)	3 (1.4%)	3 (100%)
(e) Kabuki Sd	2 (0.9%)	0
(f) DiGeorge sd	2 (0.9%)	0
(d) Comel Netherton sd	1 (0.4%)	1 (100%)
Predominantly antibody deficiencies	37 (%)	9 (24%)
(a) B absent Hypogammaglobulinemia	7 (3.3%)	2 (28%)
(b) CVID	8 (3.7%)	3 (37.5)
(c) Hyper IgM syndromes	7 (3.3%)	3 (42%)
(d) IgA deficiency	10 (4.7%)	1 (10%)
(e) Others	5 (2.3%)	0
Diseases of immune dysregulation	18 (8.4%)	9 (50%)
(a) Chediak Higashi sd	5 (2.3%)	5 (100%)
(b) Griscelli sd	2 (0.9%)	2 (100%)
(c) FHL	3 (1.4%)	0
(d)ALPS	3 (1.4%)	0
(e) ZAP-70 combined hypomorphic and activation mutations	1 (0.4%)	0
(f) IL-10Ra deficiency	1 (0.4%)	0
(g) IL-10 deficiency	1 (0.4%)	0
(h) APECED	1 (0.4%)	1 (100%)
(i) STAT3 GOF mutation	1 (0.4%)	1 (100%)
Congenital defects of phagocyte number, function, or both	57 (26.8%)	30 (52%)
(a) Neutropenia	22 (10.3%)	4 (18%)
(b) CGD	31 (14.6%)	23 (74%)
(c) GATA2 def (MonoMac sd)	1 (0.4%)	1 (100%)
(d) LAD	3 (1.4%)	2 (66.6%)
Defects in intrinsic and innate immunity	7 (3.3%)	7 (100%)
(a) CMC	3 (1.4%)	3 (100%)
(c) MSMD	3 (1.4%)	3 (100%)
(d) Epidermodysplasia verruciformis	1 (0.4%)	1 (100%)
Complement deficiencies	11 (5.1%)	6 (54.5%)
Auto-inflammatory disorders	1 (0.4%)	0
(a) TNF receptor-associated periodic syndrome; TRAPS	1 (0.4%)	0

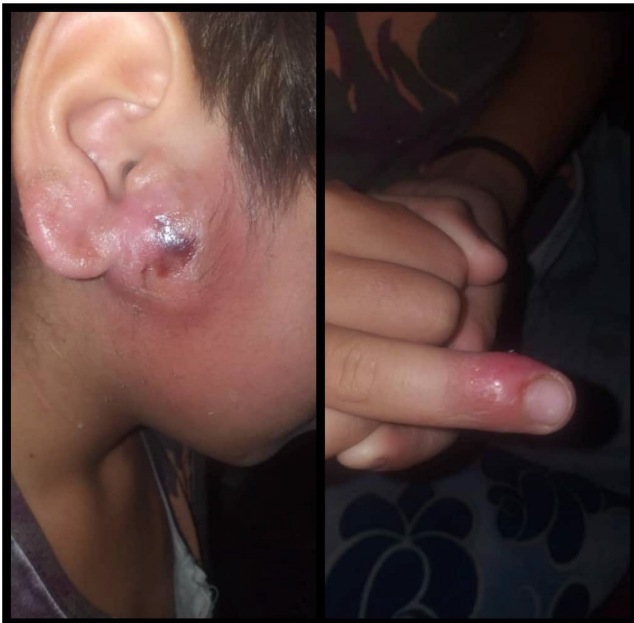Abbreviations: AD-HIES, autosomal dominant Hyper-IgE syndromes; ALPS, autoimmune lymphoproliferative syndrome; APECED, autoimmune polyendocrinopathy with candidiasis and ectodermal dystrophy; AT, ataxia telangiectasia; CGD, chronic granulomatous disease; CMC, chronic mucocutaneous candidiasis; CVID, common variable immunodeficiency; FHL, familial hemophagocytic lymphohistiocytosis; ICF1, immunodeficiency with centromeric instability and facial anomalies1; LAD, Leukocyte adhesion deficiency; MSMD, Mendelian susceptibility to mycobacterial disease; SCID, severe combined immunodeficiency; sd, syndrome; WAS, Wiskott Aldrich.

eczematous rash, especially at the presence of symptoms such as frequent severe infections, motor developmental retardation, chronic diarrhea, and failure to thrive. In previous reports, eczematous

rashes are more common among certain IEIs include Wiskott-Aldrich syndrome, Omenn syndrome, immune dysregulation, polyendocrinopathy, enteropathy X-linked, and syndromes of elevated IgE and



**FIGURE 1** Recurrent genital abscess in a 3-year-old boy with chronic granulomatous disease (CGD).



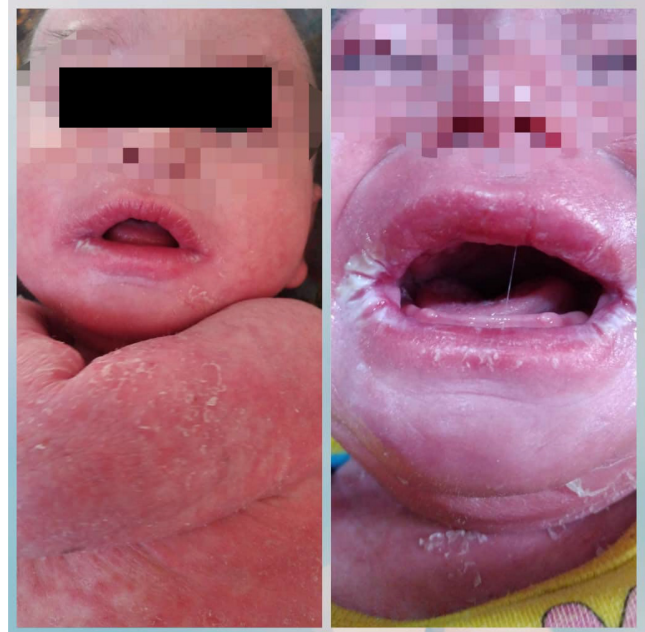**FIGURE 2** Deep cutaneous ulcers (left picture) and paronychia (right picture) in a 3-year-old boy with neutropenia.

infection because of mutations in *STAT3*, *DOCK8*, *ZNF341*, *PGM3*, *IL6ST*, *IL6R*, and *CARD11*.<sup>17</sup>

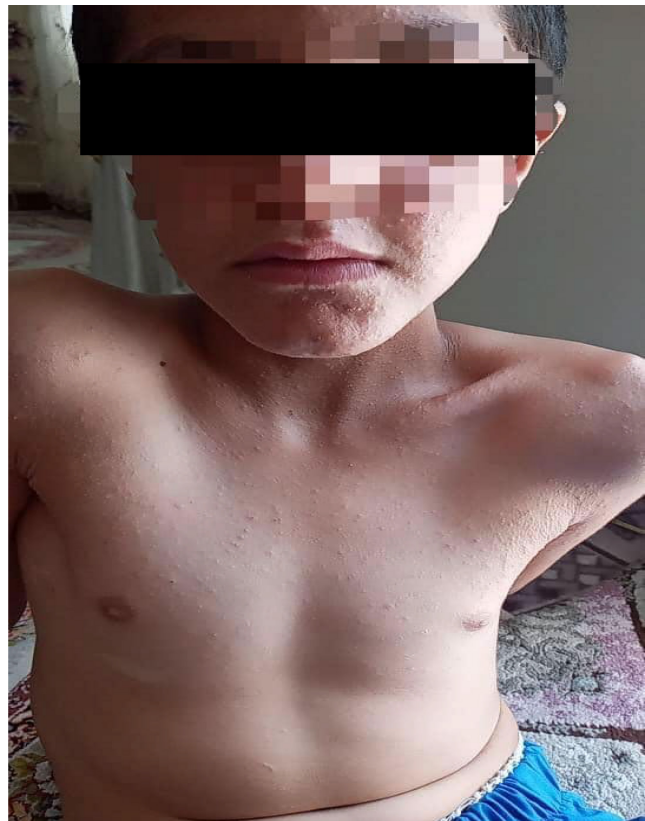In our study, five patients presented with erythroderma. In Tunisian study, erythroderma was most prevalent in PIDs classified as SCID and a consistent feature in Omenn syndrome.<sup>11</sup>

Furthermore, patients with combined immune deficiencies and defects of phagocytes were the most common diagnostic groups that accompanied by pigment alterations.

However, most skin manifestations are not pathognomonic for a specific immunodeficiency and can be detected even in immunocompetent population. Hence the regular follow-up, and close monitor for other non-dermatological manifestations such as failure to thrive, chronic diarrhea, and demographic data such as consanguinity or family history suggestive of immunodeficiency, may be helpful to define the nature of the disease.



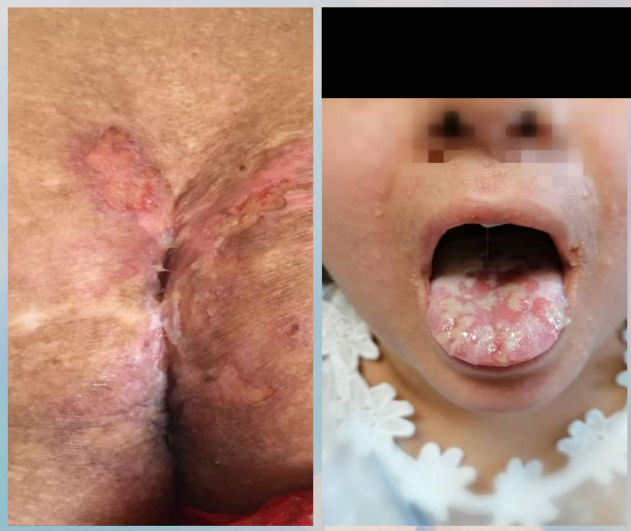**FIGURE 3** Generalized exfoliative dermatitis in a 5-month-old boy with Omenn syndrome.



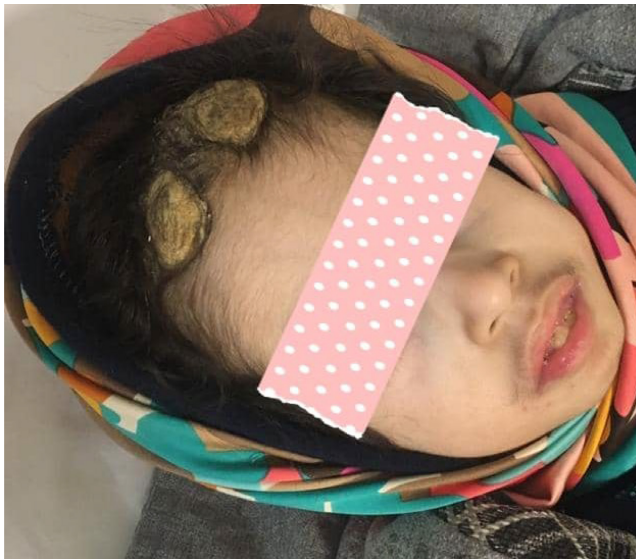**FIGURE 4** Eczematous rash in a 7-year-old boy with Hyper-IgE Syndrome.

Nevertheless, recurrent difficult-to-treat cutaneous infections (e.g., bacterial, viral, candidiasis), severe atypical eczematous dermatitis, granuloma, pigment alteration, disseminated warts, and blisters resistant to conventional treatment.





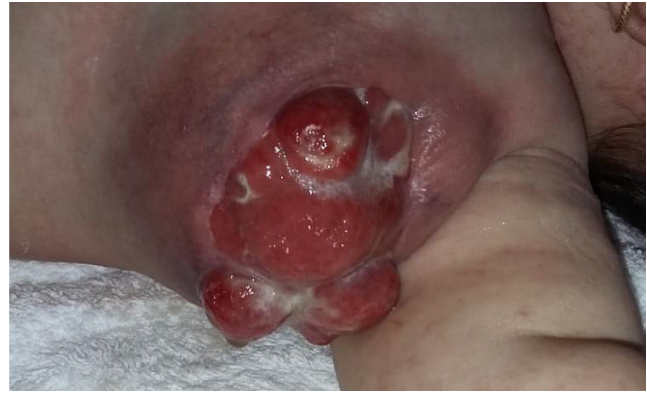**FIGURE 5** Persistent ulcerated lesions (left picture) and oral candidiasis (right picture) in a 5-year-old girl with DOCK 8 Deficiency.



**FIGURE 6** Deep dermatophytosis in a 5-year-old girl with combined immunodeficiency (CID).

This study had several limitations. The retrospective design made it hard to evaluate the impact of skin disorders on the outcome of patients. The follow-up periods were varied according to the accessibility of patients. In addition, the genetic investigations were not consistently performed for each patient. Lastly, the correlations between genotypes and phenotypes are not reliable given the small sample size.

In summary, by recent advances in immunogenetic modalities, such as targeted gene panels, whole exome, or genome analysis, our understanding of IELs is rapidly growing. Future studies can provide valuable insights into the degree to which skin manifestations in IEL patients can be a warning sign and help an early diagnosis and a more favorable outcome and better quality of life.



**FIGURE 7** Disseminated BCG disease in an infant with severe combined immunodeficiency.

#### ACKNOWLEDGMENTS

We are grateful to all patients and their families for their cooperation. This research did not receive any specific grant from funding agencies.

#### CONFLICT OF INTEREST STATEMENT

The authors declare no conflict of interest.

#### ETHICS STATEMENT

Approval of the research protocol: The study was approved by the Clinical Ethics Committee of the Shahid Beheshti University of Medical Sciences and it conforms to the provisions of the Declaration of Helsinki.

Informed Consent: Written informed consent was provided by the participants' legal guardians.

Registry and the Registration No. of the study/trial: 15674.

Animal Studies: N/A

#### ORCID

Tolue Mahdavi <https://orcid.org/0000-0002-9959-347X>

#### REFERENCES

1. Notarangelo LD, Bacchetta R, Casanova JL, Su HC. Human inborn errors of immunity: an expanding universe. *Sci Immunol*. 2020;5(49):eabb1662.
2. Tiri A, Masetti R, Conti F, Tignanelli A, Turrini E, Bertolini P, et al. Inborn errors of immunity and cancer. *Biology (Basel)*. 2021;10(4):313.
3. Scudeller L. Infectious diseases and inborn errors of immunity. *Clin Microbiol Infect*. 2022;28:1409–10.
4. Cortesi M, Soresina A, Dotta L, Gorio C, Cattalini M, Lougaris V, et al. Pathogenesis of autoimmune cytopenias in inborn errors of immunity revealing novel therapeutic targets. *Front Immunol*. 2022;13:846660.
5. Tangye SG, Al-Herz W, Bousfiha A, Cunningham-Rundles C, Franco JL, Holland SM, et al. The ever-increasing Array of novel inborn errors of immunity: an interim update by the IUIS committee. *J Clin Immunol*. 2021;41(3):666–79.
6. Karimi E, Mahmoudian F, Reyes SOL, Bargir UA, Madkaikar M, Artac H, et al. Approach to genetic diagnosis of inborn errors of immunity through next-generation sequencing. *Mol Immunol*. 2021;137:57–66.

7. López-Quintero W, Cleves D, Gomez-Vasco JD, Pérez P, Patiño J, Medina-Valencia D, et al. Skin manifestations in pediatric patients with primary immunodeficiency diseases (PIDs) in a tertiary care hospital in Colombia. *World Allergy Organ J.* 2021;14(3):100527.
8. Al-Herz W, Zainal M, Nanda A. A prospective survey of skin manifestations in children with inborn errors of immunity from a National Registry over 17 years. *Front Immunol.* 2021;12:751469.
9. Lewis DJ, Wu JH, Boyd M, Duvic M, Feldman SR. Cutaneous manifestations of genodermatoses and primary immunodeficiency. *Dermatol Online J.* 2019;25(6):2.
10. Seidel MG, Kindle G, Gathmann B, Quinti I, Buckland M, van Montfrans J, et al. The European Society for Immunodeficiencies (ESID) registry working definitions for the clinical diagnosis of inborn errors of immunity. *J Allergy Clin Immunol Pract.* 2019;7(6):1763–70.
11. Dhouib NG, Ben Khaled M, Ouederni M, Ben-Mustapha I, Kouki R, Besbes H, et al. Cutaneous manifestations of primary immunodeficiency diseases in Tunisian children. *Mediterr J Hematol Infect Dis.* 2018;10(1):e2018065.
12. Massaad MJ, Zainal M, Al-Herz W. Frequency and manifestations of autoimmunity among children registered in the Kuwait National Primary Immunodeficiency Registry. *Front Immunol.* 2020;11:1119.
13. Bousfiha A, Jeddane L, Picard C, Al-Herz W, Ailal F, Chatila T, et al. Human inborn errors of immunity: 2019 update of the IUIS phenotypical classification. *J Clin Immunol.* 2020;40(1):66–81.
14. Aluri J, Cooper MA. Genetic mosaicism as a cause of inborn errors of immunity. *J Clin Immunol.* 2021;41(4):718–28.
15. Ren A, Yin W, Miller H, Westerberg LS, Candotti F, Park CS, et al. Novel discoveries in immune dysregulation in inborn errors of immunity. *Front Immunol.* 2021;12:725587.
16. Rasouli SE, Tavakol M, Sadri H, Chavoshzadeh Z, Alireza Mahdavi S, Delavari S, et al. The spectrum of inborn errors of immunity: a single tertiary center retrospective study in Alborz, Iran. *Eur Ann Allergy Clin Immunol.* 2021;55:19–28.
17. Ghaini M, Jamee M, Mahdavi SA, Mesdaghi M, Eskandarzadeh S, Rae W, et al. The prevalence of atopic manifestations in 313 Iranian patients with inborn errors of immunity. *Int Arch Allergy Immunol.* 2021;182(11):1122–6.

**How to cite this article:** Shahrabaki ZS, Chavoshzadeh Z, Abdollahimajd F, sharafian S, Jamee M, Bondarenko A, et al. Skin manifestations in children with inborn errors of immunity in a tertiary care hospital in Iran. *J Cutan Immunol Allergy.* 2023;6:72–77. <https://doi.org/10.1002/cia2.12296>