

This is a provisional PDF only. Copyedited and fully formatted version will be made available soon.



**ISSN:** 0015-5659

**e-ISSN:** 1644-3284

## **Zygomaticofacial foramen in dry adult human skulls: a morphological study**

**Authors:** Stanislav Malakhov, Petra Lukacikova, Andrej Mifkovic, Ladislava Wsolova, Oleg Vovk, Stefan Polak

**DOI:** 10.5603/fm.100537

**Article type:** Original article

**Submitted:** 2024-05-03

**Accepted:** 2024-06-20

**Published online:** 2024-09-17

This article has been peer reviewed and published immediately upon acceptance. It is an open access article, which means that it can be downloaded, printed, and distributed freely, provided the work is properly cited.

Articles in "Folia Morphologica" are listed in PubMed.

ORIGINAL ARTICLE

DOI: 10.5603/fm.100537

Stanislav Malakhov et al., Zygomaticofacial foramen

### **Zygomaticofacial foramen in dry adult human skulls: a morphological study**

Stanislav Malakhov<sup>1</sup>, Petra Lukacikova<sup>1</sup>, Andrej Mifkovic<sup>1</sup>, Ladislava Wsolova<sup>2</sup>, Oleg Vovk<sup>3</sup>, Stefan Polak<sup>1</sup>

<sup>1</sup>Institute of Anatomy, Faculty of Medicine, Comenius University Bratislava, Bratislava, Slovakia

<sup>2</sup>Slovak Medical University, Bratislava, Slovakia

<sup>3</sup>International European University, Kyiv, Ukraine

The work was conducted at the Institute of Anatomy at the Faculty of Medicine of Comenius University in Bratislava.

**Address for correspondence:** Stanislav Malakhov, Institute of Anatomy, Faculty of Medicine, Comenius University Bratislava, Sasinkova 2, Bratislava 811 08, Slovak Republic; tel. +421 2 911 9348, email: stanislav.malakhov@fmed.uniba.sk

### **ABSTRACT**

**Background:** A wide range of medical procedures in the zygomatic region in maxillofacial surgery, implantology, and aesthetic medicine requires a detailed study of the zygomaticofacial foramen (ZFF) due to the high risk of damage to its contents during manipulation. This study aimed to estimate the shape, diameter, and location of ZFF and their relationships with anatomical landmarks.

**Materials and methods:** A study was conducted on 53 dry adult human skulls. Standard morphometric measurements were taken using sliding calipers. The number, diameter, shape, and location of ZFF were noted on both sides, and the distances between the ZFF and surrounding anatomical landmarks were measured. Conventional statistical methods were used to evaluate the data.

**Results:** Out of 106 sides, no ZFF was noticed in 2.8%, one foramen was found in 40.6%, two foramina were found in 39.6%, three in 10.4%, four in 4.7%, and five in 1.9%. The

vertical diameter was  $0.98 \pm 0.35$  mm, while the transverse diameter was  $0.87 \pm 0.31$  mm. The shape of the ZFF was oval in 67%, round in 26.2%, semilunar in 4.9%, and irregular in 1.9%. The distance from the ZFF to the infraorbital margin was  $6.63 \pm 2.09$  mm, to the frontozygomatic suture was  $26.24 \pm 3.49$  mm, to the zygomaticomaxillary suture, was  $19.75 \pm 3.55$  mm, to the zygomaticotemporal suture was  $22.31 \pm 3.98$  mm and, to the most prominent point of the zygomatic bone was  $8.03 \pm 2.64$  mm.

**Conclusions:** The variations in the number and location of ZFF must be considered while performing regional block anesthesia, and surgical or aesthetic procedures in the zygomatic region.

**Keywords:** zygomatic bone, zygomaticofacial foramen, maxillofacial surgery, craniometry, anatomical variation

## INTRODUCTION

The facial region of the skull (viscerocranium) consists of bones housing vital structures such as foramina and canals that allow nerves and blood vessels to pass through, making this area clinically significant. Among the bones of this region, the zygomatic bone (ZB) or zygoma deserves particular attention.

The ZB is an important anatomical structure in facial surgery due to its specific anatomical location [2, 6, 8]. The facial surface of the ZB is convex and pierced by the zygomaticofacial foramen (ZFF). This foramen transmits the zygomaticofacial nerve, responsible for sensory innervation of the skin over the malar prominence as well as a tiny blood vessel [4, 6, 21, 22].

The variations of the ZFF in incidence, diameter, and location have been reported in previous morphological investigations, however, a deeper understanding of these variations and their impact on surgical planning is still needed.

The clinical applications of understanding the anatomical features of the ZFF are numerous. Detailed knowledge of the ZFF is significant for the surgical treatment in maxillofacial procedures, including facial trauma, deformity, cosmetic procedures, and dental surgery when zygomatic implants are used [2, 5, 6]. Damage to the branches of the zygomatic nerve and blood vessels during these procedures can lead to subsequent complications such as loss of sensation or hematomas [14].

Moreover, it has been reported, that the ZFF has been used as an anthropological marker for distinguishing populations and ethnic groups [4].

Understanding the anatomic variations of the ZFF such as location, and frequency may improve surgery and reduce complications or minimize iatrogenic injuries [19, 20, 24].

Therefore, this study aims to investigate the anatomical variations of the ZFF in a sample of adult dry skulls, employing selected morphometric methods. By analyzing the location, frequency, and relationship of the ZFF with surrounding structures, we seek to contribute valuable insights to improve surgical planning and minimize potential complications.

## **MATERIALS AND METHODS**

Fifty-three well-preserved, contemporary dry adult human skulls (106 hemispheres) of unknown sex and age were employed in this investigation. The collection of the Institute of Anatomy, Faculty of Medicine, Comenius University in Bratislava, provided this sample. The age of the skulls ranged from newly macerated specimens to those stored in the Institute's collection for up to 30 years. Skulls were precisely selected to exclude specimens with facial bone deformities, fractures, or other pathological defects.

The methodology of our research was based on the solid foundations of previous studies with some modifications. The standard morphometric measurements were performed with manual, and digital Vernier calipers (Mitutoyo Co., Japan, accurate to 0.1 mm.) according to the recommendations of Martin and Saller (1957) and Knussmann (1988) [12, 16]. All measurements were conducted bilaterally twice, and their average was recorded in millimeters and arranged to the Microsoft Excel 2019<sup>®</sup> tables.

Following standardized positioning with the skull in the Frankfort horizontal plane, each sample experienced a detailed examination of the lateral surface of the ZB. The number of ZFF was recognized bilaterally.

Both vertical (VD) and transversal diameters (TD) of the ZFF were evaluated. The VD was measured from the superior margin to the inferior margin of the foramen, whereas TD was measured between the medial and lateral margins, respectively (Fig. 1).

Based on their VD and TD measurements, the foramina were classified into two categories: the main zygomaticofacial foramen (mZFF) and accessory foramina (aZFF). The mZFF was identified as the foramen with the largest diameters, while aZFF denoted the presence of additional foramina on a single side. Furthermore, the shape of the mZFF was evaluated based on the correlation between the VD and TD values, with the following criteria:

1. When the VD and TD values differed by less than 10%, the ZFF was considered round in shape.

2. When the VD and TD values diverged between 10-50%, the ZFF was considered oval.

3. When the VD and TD values diverged by more than 50%, the ZFF was considered semilunar.

The lateral surface of ZB was subdivided into nine regions marked by the Roman numbers from I to IX with two vertical and two horizontal lines (Fig. 1). Vertical lines were drawn from the frontomolare orbitale (FMO, frontozygomatic suture at the orbital margin) and frontomolare temporale (FMT, most laterally placed point on the frontozygomatic suture) cranial points. Horizontal lines from the cranial points including the zygomaticotemporale superior (ZTS, upper point of the zygomaticotemporal suture) and zygomaticotemporale inferior (ZTI, lower point of the zygomaticotemporal suture) cranial points were drawn. The location of the mZFF was detected according to the regions mentioned above.

The distances from the mZFF to the nearest point of the infraorbital margin (IOM), to the middle point of the frontozygomatic suture (FZS), to the lowest point of the zygomaticomaxillary suture (ZMS), to the middle point of the zygomaticotemporale suture (ZTS) and, to the most prominent point of the lateral surface of the zygomatic bone (ZP) were established (Fig. 2).

The distances from the mZFF to each aZFF were measured and estimated. All aZFF were numbered according to their location from the superior to inferior parts of the ZB.

Further, we estimated the location of the mZFF concerning the ZP according to a clockwise. An imaginary clock face superimposed on the ZP point was used, and the position of the foramen was established (Fig. 3).

The statistical evaluation of the data was performed using IBM SPSS Statistics for Windows, Version 28.0 (IBM Corp., Armonk, NY, USA). Conventional statistical methods were applied to data evaluation including average mean, standard deviation, range, and confidential interval. The normality of the data distribution was assessed using the Shapiro-Wilk test. The Chi-Square and Fisher's Exact Test in contingency tables were performed to test the relationship between two categorical variables. The paired Wilcoxon Signed Ranks Test and paired t-test were used for the comparison of measured variables such as diameter and distances on the left and right sides of the skull. Statistical differences were considered when the p-value was less than or equal to 0.05.

## **RESULTS**

ZFF was detected in 52 of the 53 investigated skulls (103 hemicrania). All foramina found on the lateral surface of the ZB were described as ZFF and subdivided into mZFF and aZFF. Among all the samples were estimated 103 mZFF and 85 aZFF.

The number of the ZFF ranged from 0 to 5 (Fig. 4). The most frequent one (single) foramen was observed in 40.6% and two (double) foramina in 39.6% (Table 1). There was a statistically significant dependence in the numbers of foramina between the left and right sides ( $P < 0.001$ ). One sample exhibited bilateral absence of the foramen, and another showed unilateral absence. An equal number of foramina on the right and left sides was established on 32 skulls, while 21 displayed asymmetry in the number of foramina. Predomination on the right side (more foramina) was detected on 15 samples, and the left side on 6 samples, respectively. No statistical differences in the predomination of foramina were observed between the right and left sides ( $P = 0.123$ ).

The mean of the VD was found to be  $0.98 \pm 0.35$  mm, and the range was 0.32–2.5 mm, while the mean of the TD was  $0.87 \pm 0.31$  mm, and the range was 0.31–2.81 mm (Fig. 5). The predominance of values of VD over TD ( $VD > TD$ ) was found on 71 hemicrania (68.9%), and predominance of TD over VD ( $TD > VD$ ) was estimated on 29 sides (28.2%), respectively. Only three sides of the 103 investigated hemicrania showed equal meanings of VD and TD (2.9%). There was a statistically significant dependence between the left and right sides in the TD ( $P = 0.04$ ) and no statistical significance in the VD ( $P = 0.68$ ).

Variations in the mZFF shape were observed. Oval was the most prevalent shape (67%), followed by round (26.2%), semilunar (4.9%), and irregular (1.9%) (Fig. 6). Bilateral symmetry in mZFF shape was found in 39 out of 53 skulls (73.6%). A statistically significant dependence between the left and right sides regarding mZFF shape was identified ( $P < 0.001$ ).

The frequency of the location of mZFF according to the regions of the lateral surface of ZB is shown in Fig 7. Most frequently, mZFF was located in regions number II, IV, and V in 20.4, 22.3, and 52.3% respectively. However, none of the foramina were observed in regions VII and IX, one foramen occasionally was found in region VIII. The majority of the ZFF found in regions II, IV, and V were situated close to the intersection of the anterior vertical and superior horizontal lines, designated as the A-point (Fig. 7). Twenty-four skulls exhibited a bilaterally symmetrical mZFF location. There was a statistically significant dependence between the left and right sides ( $P = 0.038$ ).

The distances from the ZFF to the selected surrounding anatomical landmarks were identified and presented in Table 2. The average mean of the mZFF-IOM distance was  $6.63 \pm 2.09$  mm, the mZFF-FZS distance was  $26.24 \pm 3.49$ , the mean of the mZFF-ZMS distance

was  $19.75 \pm 3.55$  mm, the mZFF-ZTS distance was  $22.31 \pm 3.98$  mm, and the mZFF-ZP distance  $8.03 \pm 2.64$  mm (Fig. 2). The statistical significance between right and left sides was found to be in mZFF-ZMS ( $P = 0.001$ ) and mZFF-ZTS ( $P = 0.03$ ) distances. All the rest measured distances did not show statistical significance.

A total of 85 aZFF were detected across all samples. The number of aZFF on a single side of the skull ranged from 1 to 4. The mean distance between the mZFF and aZFF was  $7.87 \pm 4.39$  mm, with a range of 1.22 mm to 22.00 mm. No statistical significance was established between the right and left sides ( $P = 0.32$ ).

The ZP points were selected as a crucial anatomical landmark due to their palpability on the face. An imaginary clock face was superimposed on the ZP point. The distribution of the mZFF location is represented in Fig. 8. On the right side, mZFF was most frequently located at the 2 o'clock (23.1%), 11 o'clock (25.0%), and 12 o'clock (28.9%) positions. On the left side, foramina were most frequently detected at the 1 o'clock (25.4%), 11 o'clock (28.2%), and 12 o'clock (31.1%) positions. No mZFF were observed at the 4, 5, 6, 7, or 9 o'clock positions on either side. Our findings suggest that the mZFF is more frequently located superior (cranial) to the ZP point. A statistically significant difference in mZFF location was identified between the left and right sides ( $P < 0.001$ ).

## DISCUSSION

Knowledge of the ZFF is of crucial importance for practical medicine during surgical interventions in this area. Previous studies have been conducted using the method of assessing the foramina on dry skulls [1, 2, 4, 6, 7, 13–15, 17, 18, 24], isolated ZB [19], cadavers [8, 20], and through the analysis of computer tomography images [3, 9, 11]. In addition, some researchers have compared morphometric data obtained from physical examination of dry skulls or cadavers with data obtained from CT images [5]. The variability in the number of foramina is most commonly attributed to the embryologic aspects due to different numbers of ossification centers of the zygoma [24].

The presence of aZFF can elevate the risk of damaging the neurovascular structures of these foramina. The number of ZFF has been a widely researched issue. Previous studies have reported varying numbers of ZFFs, ranging from 0 to 3 [13], 0 to 4 [4, 5, 7, 9, 14, 15, 18], and 0 to 5 [1, 16, 24]. Nteli Chatzioglou et al. [19] reported a range from 0 to 6 foramina, while Zhao Y. et al. [24] provided the average number of foramina  $1.98 \pm 0.93$ . The most common number of ZFFs observed was one, which ranged from 30.4% [19] to 53.3% [4]. Two foramina were detected from 12.12% [13] to 32.7% of cases [9], which corresponds to

our investigation. However, most of the previous publications suggest a higher percentage of the absence of foramina compared to our study, with a range of 21.8%. In contrast, our study found only a 2.8% absence of foramina, which aligns with the results of the study conducted by Zhao Y et al. [24]. Mokryk et al. [18] in their study reported no absence of ZFF.

It has been reported in the literature that the absence of the zygomaticofacial nerve may occur in the absence of ZFF in such cases, the other branches of the trigeminal nerve join with the zygomaticofacial nerve to provide sensory innervation of the malar skin [15]. Previous studies have reported statistics on the number of foramina in different ethnic groups, sexes, or types of skull structure. While some studies have indicated a significant difference between sexes [9], others have found no significant difference in the number of foramina between men and women [4, 6].

The diameter of the ZFF serves as a valuable indicator of nerve damage risk during facial surgery. The data on the ZFF diameter allows us to estimate the potential size of nerves that pass through. Previous studies have reported that there is a correlation between the diameter of the foramen and the development of nerve paresthesia [24].

In our study, we have estimated both VD and TD of ZFF in an average mean of  $0.98 \pm 0.35$  mm and  $0.87 \pm 0.31$  mm, respectively. Natalia Bigelli Del Neri et al. [5] reported that the average diameter of ZFF was  $0.57 \pm 0.27$  mm, ranging from 0.16–1.00 mm. Carvalho et al. [2] estimated that the mean ZFF diameter was in males  $1.083 \pm 0.285$  mm on the right side and  $1.108 \pm 0.311$  mm on the left side, respectively. In females was  $1.092 \pm 0.265$  mm on the right hemicranium and  $1.077 \pm 0.278$  mm on the left hemicranium, respectively. The rate of the diameter varied from 0.3 to 1.85 mm [3]. Kawata et al. [9] in their cadaver study (micro-CT analysis of 52 cadavers) reported: that the mean ZFF diameters were 1.09 mm (SD 0.31 mm) in males and 1.03mm (SD 0.32 mm) in females. No significant sex-related difference in ZFF diameter was observed. Coutinho et al. [2] evaluated the VD and TD of ZFF. Although the authors did not mention the exact data obtained, they reported that significantly higher vertical diameters were found in the ZFF located on the left side of the skulls. Additionally, they found no significant correlations between the VD and TD of ZFF.

The evaluation of foramen shape is necessary for determining needle placement during anesthetic block administration [2]. According to Coutinho et al. [2], the circular format was the most common shape of the ZFF, accounting for 63.9% on the right side and 50.8% on the left side. They also reported that the oval shape was the second most frequent shape, which accounted for 36.1% and 49.2% on the right and left sides, respectively. Our study revealed that the oval shape was the most prevalent for the ZFF, accounting for 67% of



the observed foramina. The round shape was the second most frequent, identified in 26.2% of the cases. It's important to note that the authors reported that no semilunar shapes of ZFF were found, which is not consistent with our results (4.9%).

In previous studies, authors have used various methods to define the location of ZFF on the surface of the ZB. These methods have involved dividing the lateral surface of the ZB into zones, regions, or sectors. The lateral surface of ZB was divided into four regions using horizontal and vertical lines drawn across the upper border of the zygomatic arch and a vertical line on the lateral orbital rim [1, 4, 7, 13, 19]. Previous studies have reported that the ZFF is most frequently located in region “C” — posterior to the vertical line and superior to the horizontal line.

In the study by Ferro et al. [6], lines were drawn through the Frankfurt horizontal plane and the posterior border of the frontozygomatic suture. In addition, in the study by Kawata et al. [9], the main reference point for establishing the position of the ZFF was the line between the craniometric points Ju and ZM.

In our study, we used two horizontal and two vertical lines drawn perpendicular to the craniometric points, which allowed us to divide the surface of the ZB into nine regions for a more precise spatial characterization of the position of the ZFF. Our investigation established that the ZFF was most frequently located in region V, corresponding to the middle of the lateral surface of the ZB.

Determining the precise location of the foramen is important for facial surgery. Our research focused on the relationships between the ZFF and surrounding anatomical landmarks, including the IOM, FZS, ZMS, and ZTS due to their clinical importance reported in the literature [1, 2, 19]. Our study found a ZFF-IOM distance of  $6.63 \pm 2.09$  mm, which aligns with the findings of Nteli Chatzioglou et al. [19]. The literature reports an average ZFF-IOM distance ranging from 1.2 to 11 mm [8, 14]. Deana et al. [4] observed that this distance can vary depending on the ZFF location. Regarding the ZFF-FZS distance, our research established an average of  $26.24 \pm 3.49$  mm, similar to the findings of Aksu et al. [1]. Hwang et al. [7] reported a smaller average mean of distance 24.4 mm, whereas Coutinho et al. [2] obtained a distance of 27.49 mm. Previous studies reported an average ZFF-ZMS distance ranging from 17.50 mm to 20.05 mm [2, 13]. Our study established an average of  $19.75 \pm 3.55$  mm. The distance between ZFF and ZTS was  $22.31 \pm 3.98$ , which is consistent with the data of Coutinho et al. [2].

Previous studies have investigated the distances between the ZFF and other selected anatomical landmarks. Hwang et al. [7] reported that the ZFF was located 7.3 mm lateral and

3.7 mm inferior to a point (P) defined by the intersection of a line drawn along the upper border of the zygomatic arch and a vertical line on the lateral orbital rim. Additionally, the ZFF was found to be located 11.0–13.0 mm from the zygomatic angle [7, 17]. In our study, we observed that most mZFF were situated close to a newly defined reference point, designated as the A-point (see Fig. 7). However, no measurement of the distance between ZFF and this point was undertaken in our study.

Kawata et al. [9] established that the location of ZFF, which is relevant to zygomatic implant treatment, could be determined by selecting a reference line connecting the Jugale and Zygomaticomaxillare cranial points. The average distance was found to be  $12.36 \pm 1.52$  mm (for males) and  $11.48 \pm 1.61$  mm (for females). The study by Nteli Chatzioglou [19] measured the distance between ZFF and the maxillary process of Zygomatic Bone (ZB), which was determined to be  $21.56 \pm 4.16$  mm.

A significant question concerns identifying or predicting the ZFF location in living individuals. Our study examined this further by investigating the location of the ZFF relative to the ZP, the most lateral point on the lateral surface of the ZB. This easily identifiable landmark makes the ZP a simple and reliable reference point for ZFF localization in clinical settings. The distance from this point to the ZFF was measured, which was  $8.03 \pm 2.64$  mm and the range was 2.75–15.0 mm. Furthermore, we assessed the foramen's relative position using an imaginary clock face superimposed on the ZP. The analysis revealed that on the right side, the ZFF was most frequently located at the 2 o'clock (23.1%), 11 o'clock (25.0%), and 12 o'clock (28.9%) positions. Similarly, on the left side, foramina were most commonly detected at the 1 o'clock (25.4%), 11 o'clock (28.2%), and 12 o'clock (31.1%) positions.

During surgery in the zygomatic region, the presence of aZFF can increase the risk of nerve damage. Previous studies [1, 17] have highlighted this possibility and urged surgeons to take precautions to avoid injuring these nerves. However, only one study has provided information on the location and distance of aZFF concerning the main foramen. Martins et al. [17] reported that in cases where multiple zygomaticofacial foramina were present, the openings were arranged along a line parallel to the orbital margin. The average distance between multiple foramina was 0.5 cm (range 0.1–1.3 cm). Our study established that the average distance between mZFF and aZFF was  $7.87 \pm 4.39$  mm, with a range of 1.22 to 22.00 mm. Although there is still a lack of data on the exact location of aZFF, this information can be helpful for surgeons to plan their procedures and minimize the risk of nerve damage.

## CONCLUSIONS

The presence and contents of the ZFF contribute to the clinical significance of the zygomatic region. The variations in the number and location of ZFF must be considered when managing regional block anesthesia, carrying out surgical procedures, or performing aesthetic treatments in the zygomatic region, especially close to the infraorbital margin. Neglecting this crucial aspect can lead to complications and unwanted results and consequences that could have been avoided with proper consideration.

Our study of the ZFF and its variations could contribute significantly to clinical medicine due to the detailed analysis of the foramen, including its shape, location, size, and its relationships with the surrounding anatomical landmarks.

## **Article information and declarations**

### ***Data availability statement***

The data sets used and/or analyzed during the current study are available from the corresponding author on reasonable request.

### ***Ethics statement***

Ethics approval was not required. Body donors have provided informed consent for their bodies to be used for scientific research within the Institute of Anatomy of Comenius University in Bratislava.

### ***Author contributions***

**Stanislav Malakhov:** project development, data collection and managements, manuscript writing and editing. **Petra Lukacikova:** project development, data collection and managements, manuscript writing and editing. **Andrey Mifkovic:** manuscript writing and editing. **Ladislava Wsolova:** data analysis and managements, manuscript writing and editing. **Oleg Vovk:** project development, manuscript writing and editing. **Stefan Polak:** manuscript writing and editing.

### ***Funding***

he authors received no funding for this project.

### ***Acknowledgments***

The authors sincerely thank those who donated their bodies to science so that anatomical research could be performed. Results from such research can potentially increase mankind's overall knowledge that can then improve patient care. Therefore, these donors and their families deserve our highest gratitude.

### ***Conflict of interest***

The authors declare that they have no competing interests.

## References

1. Aksu F, Ceri NG, Arman C, et al. Location and incidence of the zygomaticofacial foramen: an anatomic study. *Clin Anat*. 2009; 22(5): 559–562, doi: [10.1002/ca.20805](https://doi.org/10.1002/ca.20805), indexed in Pubmed: [19418451](https://pubmed.ncbi.nlm.nih.gov/19418451/).
2. Coutinho DC, Martins-Júnior PA, Campos I, et al. Zygomaticofacial, zygomaticoorbital, and zygomaticotemporal foramina. *J Craniofac Surg*. 2018; 29(6): 1583–1587, doi: [10.1097/SCS.0000000000004530](https://doi.org/10.1097/SCS.0000000000004530), indexed in Pubmed: [29570528](https://pubmed.ncbi.nlm.nih.gov/29570528/).
3. Carvalho C, Tolentino E, Herreira-Ferreira M, et al. Anatomical in vivo study of variations in zygomatic bone: pneumatization and foramina. *Acta Scientiarum. Health Sciences*. 2022; 45: e58021, doi: [10.4025/actascihealthsci.v45i1.58021](https://doi.org/10.4025/actascihealthsci.v45i1.58021).
4. Deana NF, Alves N. Frequency and location of the zygomaticofacial foramen and its clinical importance in the placement of zygomatic implants. *Surg Radiol Anat*. 2020; 42(7): 823–830, doi: [10.1007/s00276-020-02455-1](https://doi.org/10.1007/s00276-020-02455-1), indexed in Pubmed: [32246188](https://pubmed.ncbi.nlm.nih.gov/32246188/).
5. Del Neri NB, Araujo-Pires AC, Andreo JC, et al. Zygomaticofacial foramen location accuracy and reliability in cone-beam computed tomography. *Acta Odontol Scand*. 2014; 72(2): 157–160, doi: [10.3109/00016357.2013.814804](https://doi.org/10.3109/00016357.2013.814804), indexed in Pubmed: [23808498](https://pubmed.ncbi.nlm.nih.gov/23808498/).
6. Ferro A, Basyuni S, Brassett C, et al. Study of anatomical variations of the zygomaticofacial foramen and calculation of reliable reference points for operation. *Br J Oral Maxillofac Surg*. 2017; 55(10): 1035–1041, doi: [10.1016/j.bjoms.2017.10.016](https://doi.org/10.1016/j.bjoms.2017.10.016), indexed in Pubmed: [29122337](https://pubmed.ncbi.nlm.nih.gov/29122337/).
7. Hwang SeHo, Jin S, Hwang K. Location of the zygomaticofacial foramen related to malar reduction. *J Craniofac Surg*. 2007; 18(4): 872–874, doi: [10.1097/scs.0b013e3180a03353](https://doi.org/10.1097/scs.0b013e3180a03353), indexed in Pubmed: [17667680](https://pubmed.ncbi.nlm.nih.gov/17667680/).
8. Iwanaga J, Badaloni F, Watanabe K, et al. Anatomical study of the zygomaticofacial foramen and its related canal. *J Craniofac Surg*. 2018; 29(5): 1363–1365, doi: [10.1097/SCS.0000000000004457](https://doi.org/10.1097/SCS.0000000000004457), indexed in Pubmed: [29521755](https://pubmed.ncbi.nlm.nih.gov/29521755/).
9. Kawata K, Ide Y, Sunohara M. Anatomical study of the zygomaticofacial foramen and zygomatic canals communicating with the zygomaticofacial foramen for zygomatic implant treatment: a cadaver study with micro-computed tomography analysis. *Anat Cell Biol*. 2024; 57(2): 204–212, doi: [10.5115/acb.23.293](https://doi.org/10.5115/acb.23.293), indexed in Pubmed: [38237948](https://pubmed.ncbi.nlm.nih.gov/38237948/).
10. Khalid S, Iwanaga J, Loukas M, et al. Bilateral absence of the zygomatic nerve and zygomaticofacial nerve and foramina. *Cureus*. 2017; 9(7): e1505, doi: [10.7759/cureus.1505](https://doi.org/10.7759/cureus.1505), indexed in Pubmed: [28948125](https://pubmed.ncbi.nlm.nih.gov/28948125/).
11. Kim HS, Oh JH, Choi DY, et al. Three-dimensional courses of zygomaticofacial and zygomaticotemporal canals using micro-computed tomography in Korean. *J Craniofac Surg*. 2013; 24(5): 1565–1568, doi: [10.1097/SCS.0b013e318299775d](https://doi.org/10.1097/SCS.0b013e318299775d), indexed in Pubmed: [24036727](https://pubmed.ncbi.nlm.nih.gov/24036727/).
12. Knussman R. *Anthropologie. Handbuch der vergleichenden Biologie des Menschen*. Gustav Fischer Verlag, New York 1988: 744.
13. Lone M, Telang A, Rajgopal L, et al. Location and incidence of the zygomatico-facial foramen in dry human skulls: An anatomical study. *J Anat Soc India*. 2016; 65(2): 164–166, doi: [10.1016/j.jasi.2017.01.001](https://doi.org/10.1016/j.jasi.2017.01.001).
14. Loukas M, Owens DG, Tubbs RS, et al. Zygomaticofacial, zygomaticoorbital and zygomaticotemporal foramina: anatomical study. *Anat Sci Int*. 2008; 83(2): 77–82, doi: [10.1111/j.1447-073X.2007.00207.x](https://doi.org/10.1111/j.1447-073X.2007.00207.x), indexed in Pubmed: [18507616](https://pubmed.ncbi.nlm.nih.gov/18507616/).

15. Mangal A, Choudhry R, Tuli A, et al. Incidence and morphological study of zygomaticofacial and zygomatico-orbital foramina in dry adult human skulls: the non-metrical variants. *Surg Radiol Anat.* 2004; 26(2): 96-99, doi: [10.1007/s00276-003-0198-7](https://doi.org/10.1007/s00276-003-0198-7), indexed in Pubmed: [15004726](https://pubmed.ncbi.nlm.nih.gov/15004726/).
16. Martin R, Saller K. 1957: *Lehrbuch der Anthropologie. Band I.* G FisherVerlag, Stuttgart 1957: 661.
17. Martins C, Li X, Rhoton AL. Role of the zygomaticofacial foramen in the orbitozygomatic craniotomy: anatomic report. *Neurosurgery.* 2003; 53(1): 168-72; discussion 172, doi: [10.1227/01.neu.0000068841.17293.bb](https://doi.org/10.1227/01.neu.0000068841.17293.bb), indexed in Pubmed: [12823886](https://pubmed.ncbi.nlm.nih.gov/12823886/).
18. Mokryk O, Hadzik J, Shybinskyy V. Development of the method of conducting anesthesia of zygomaticofacial nerve in people with different face shape and its clinical evaluation. *J Stomatol.* 2019; 72(6): 245-251, doi: [10.5114/jos.2019.93843](https://doi.org/10.5114/jos.2019.93843).
19. Nteli Chatzioglou G, Sağlam L, Çandır BN, et al. Anatomical variations of the zygomaticofacial foramen and its related canal through the zygomatico-orbital and zygomaticotemporal foramina in dry human skulls. *Surg Radiol Anat.* 2024; 46(1): 33-40, doi: [10.1007/s00276-023-03257-x](https://doi.org/10.1007/s00276-023-03257-x), indexed in Pubmed: [38092974](https://pubmed.ncbi.nlm.nih.gov/38092974/).
20. Siddiqui HF, Konschake M, Ottone NE, et al. A marginal process of the zygomatic bone predicts a lateral exit of the zygomaticotemporal nerve: An anatomical study with application to surgery around the midface. *Clin Anat.* 2023; 36(5): 708-714, doi: [10.1002/ca.24021](https://doi.org/10.1002/ca.24021), indexed in Pubmed: [36752958](https://pubmed.ncbi.nlm.nih.gov/36752958/).
21. Snell RS. *Clinical anatomy for medical students.* Little, Brown and Company, Boston 1995.
22. Standring S. *Gray's Anatomy, The Anatomical Basis of Clinical Practice,* 41.ed. Elsevier, London 2016.
23. Zacharopoulos GV, Manios A, Kau CH, et al. Anthropometric analysis of the face. *J Craniofac Surg.* 2016; 27(1): e71-e75, doi: [10.1097/SCS.0000000000002231](https://doi.org/10.1097/SCS.0000000000002231), indexed in Pubmed: [26703056](https://pubmed.ncbi.nlm.nih.gov/26703056/).
24. Zhao Y, Chundury RV, Blandford AD, et al. Anatomical description of zygomatic foramina in african american skulls. *Ophthalmic Plast Reconstr Surg.* 2018; 34(2): 168-171, doi: [10.1097/IOP.0000000000000905](https://doi.org/10.1097/IOP.0000000000000905), indexed in Pubmed: [28369018](https://pubmed.ncbi.nlm.nih.gov/28369018/).

**Table 1.** Number of the ZFF among all the samples.

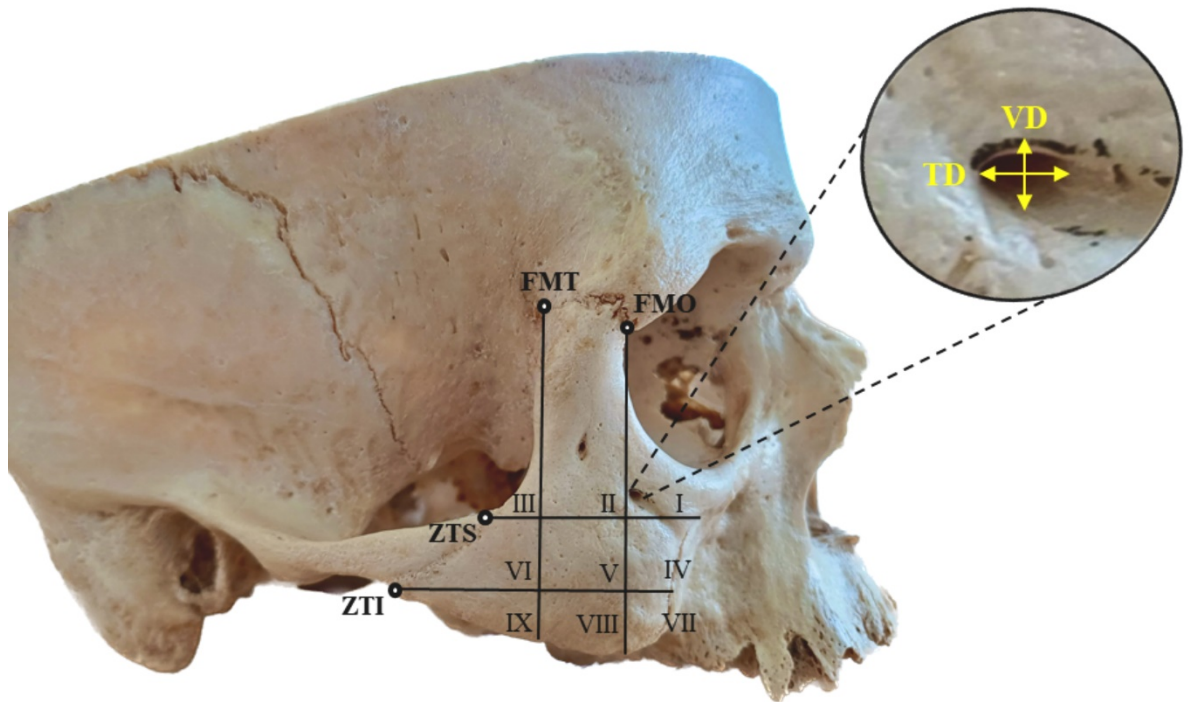
Side Numbers	Overall (n = 106)		Right side (n = 53)		Left side (n = 53)	
	%	n	%	n	%	n
0	2.8	3	1.9	1	3.8	2
1	40.6	43	39.6	21	41.5	22
2	39.6	42	39.6	21	39.6	21
3	10.4	11	9.4	5	11.3	6
4	4.7	5	5.7	3	3.8	2
5	1.9	2	3.8	2	0	0

**Table 2.** Distances between the mZFF and anatomical landmarks (in mm).

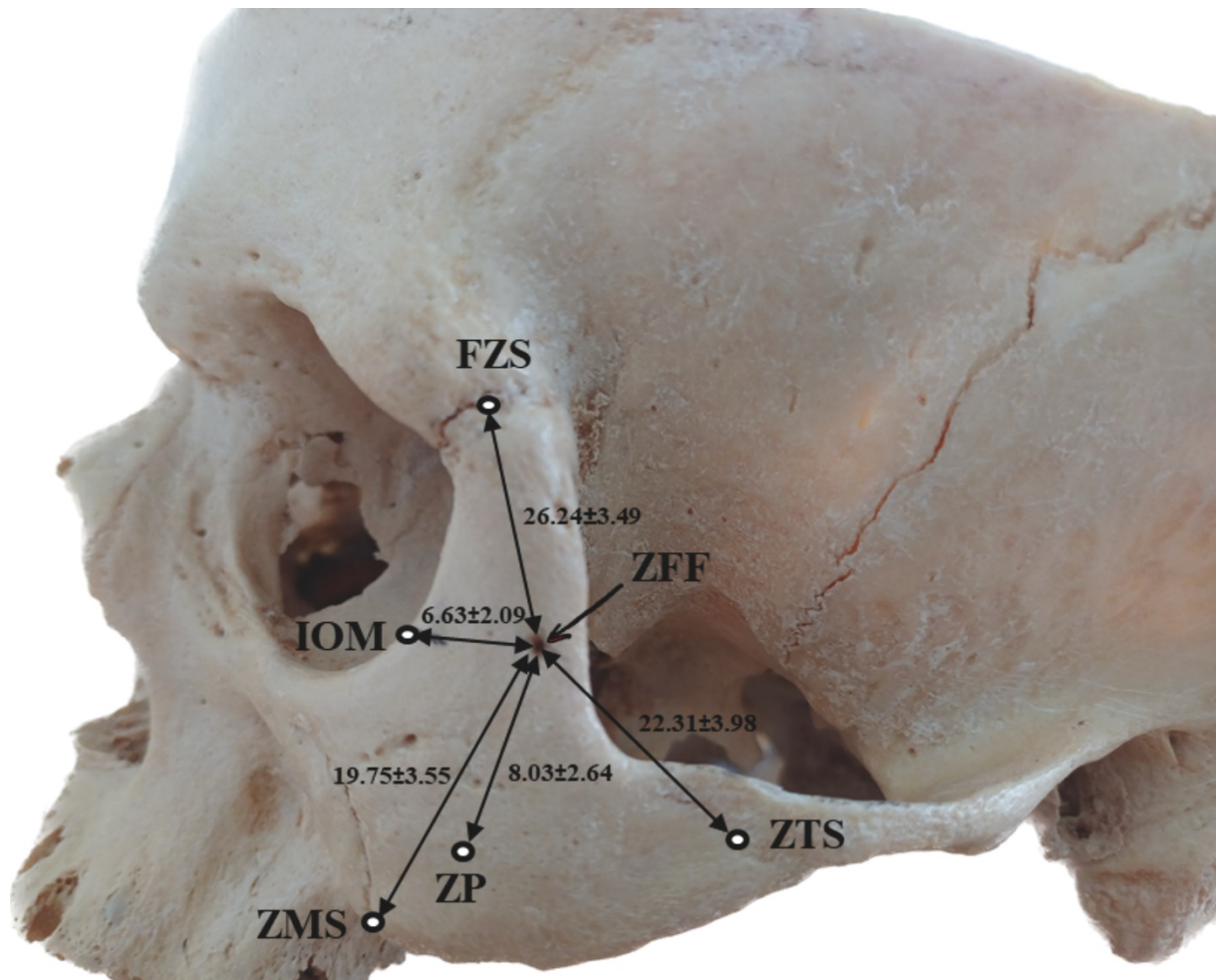
Measured parameter	Side	Samples	Mean±SD	Range	Confidential interval	P-value
--------------------	------	---------	---------	-------	-----------------------	---------

					<b>(95%)</b>	
mZFF-IOM	Right	52	6.52 ± 1.95	3.39–12.75	5.98–7.06	0.56*
	Left	51	6.74 ± 2.24	2.75–13.75	6.11–7.37	
	Overall	103	6.63 ± 2.09	2.75–13.75	6.16–7.0	
mZFF-FZS	Right	52	26.32 ± 3.32	20.25–34.78	25.39–27.24	0.9*
	Left	51	26.16 ± 3.70	17.5–34.0	25.12–27.20	
	Overall	103	26.24 ± 3.49	17.5–34.78	25.56–26.92	
mZFF-ZMS	Right	52	19.46 ± 3.45	9.36–26.7	18.50–20.43	0.001*
	Left	51	20.03 ± 3.66	9.6–29.76	19.00–21.06	
	Overall	103	19.75 ± 3.55	9.36–29.76	19.05–20.44	
mZFF-ZTS	Right	52	22.82 ± 4.29	13.27–33.11	21.62–24.02	0.03**
	Left	51	21.78 ± 3.61	11.92–28.1	20.76–22.79	
	Overall	103	22.31 ± 3.98	11.92–33.11	21.53–23.08	
mZFF-ZP	Right	52	7.92 ± 2.66	3.84–13.84	7.18–8.66	0.66**
	Left	51	8.14 ± 2.64	2.75–15.0	7.39–8.88	
	Overall	103	8.03 ± 2.64	2.75–15.0	7.51–8.54	

\*Wilcoxon Signed Ranks Test and paired t-test, \*\*Paired t-test.

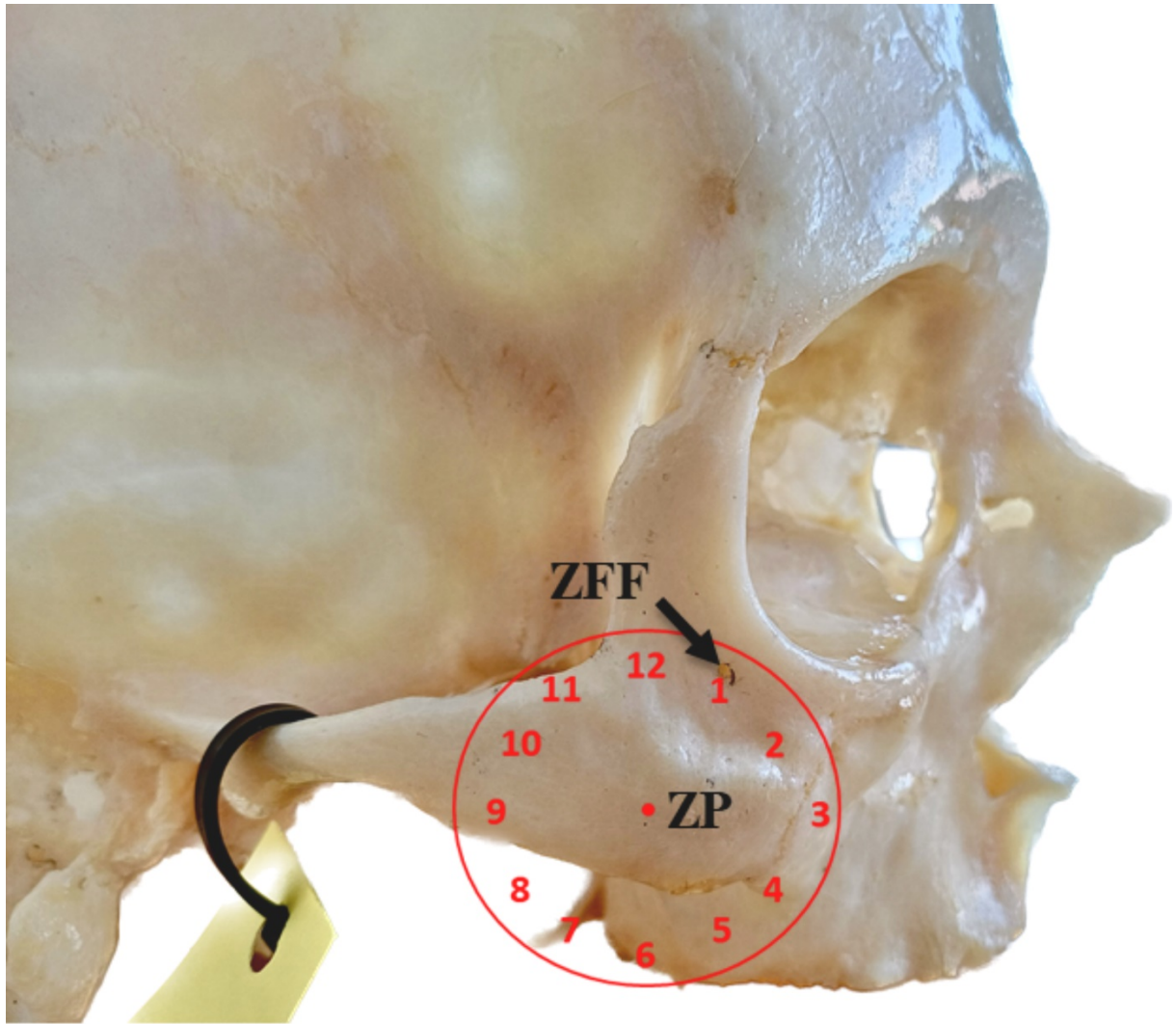


**Figure 1.** Regions on the lateral surface of the ZB (I-IX) and measured diameters of the mZFF. FMO — frontomolare orbitale; FMT — frontomolare temporale; TD — transverse diameter; VD — vertical diameter; ZTI — zygomaticotemporale inferior; ZTS — zygomaticotemporale superior;

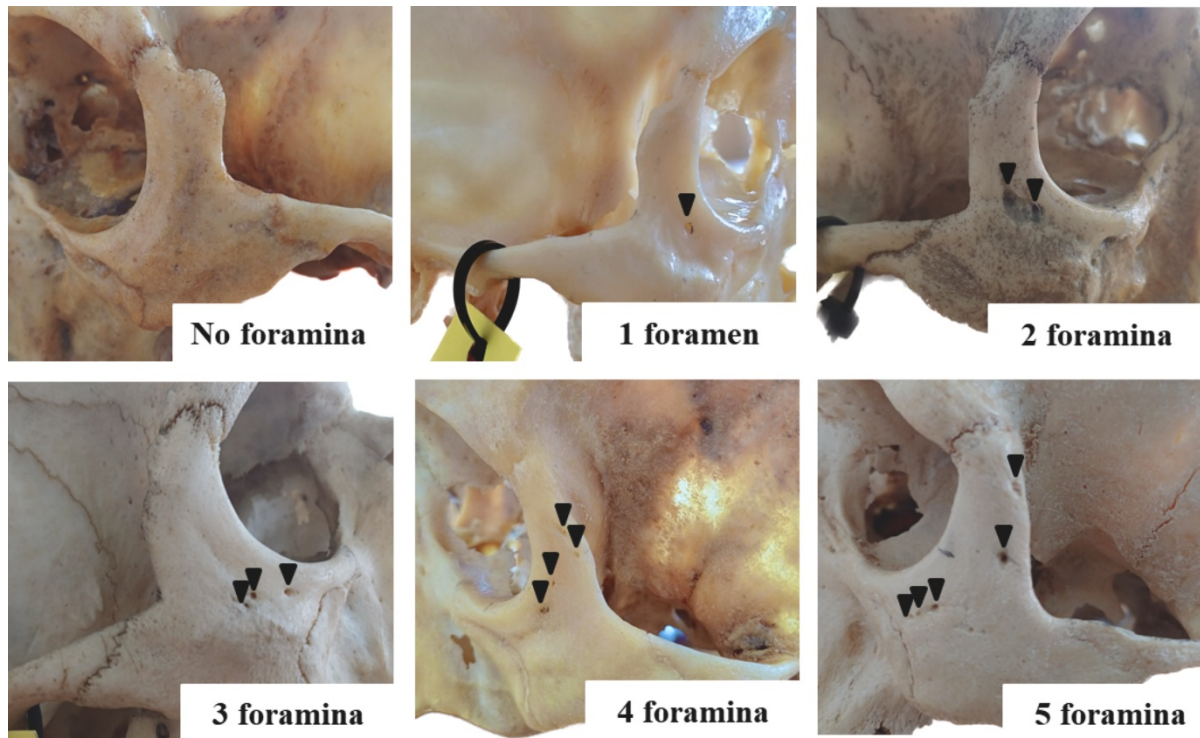


**Figure 2.** Measured distances (mm) from the mZFF to selected anatomical landmarks and their corresponding average values. FZS — frontozygomatic suture; IOM — infraorbital margin; ZFF — zygomaticofacial foramen; ZMS — zygomaticomaxillary suture; ZP — zygomatic prominence; ZTS — zygomaticotemporal suture;

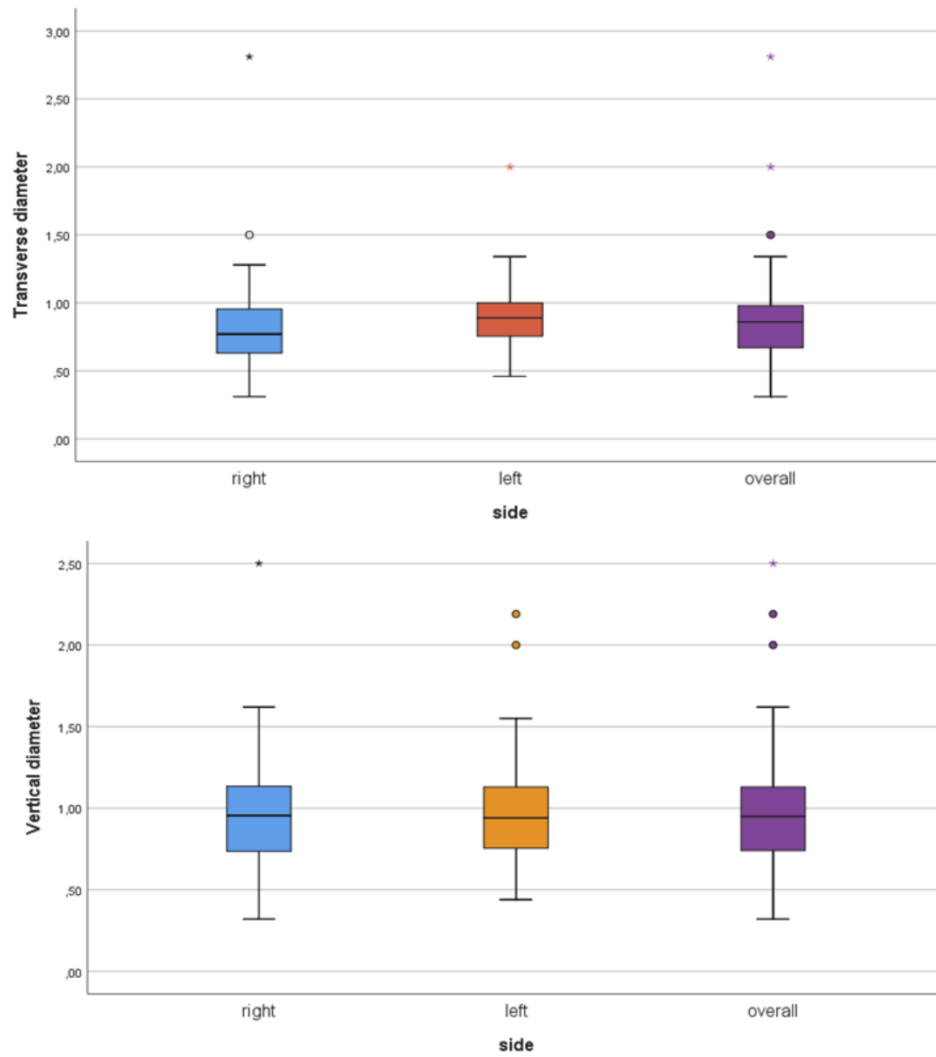




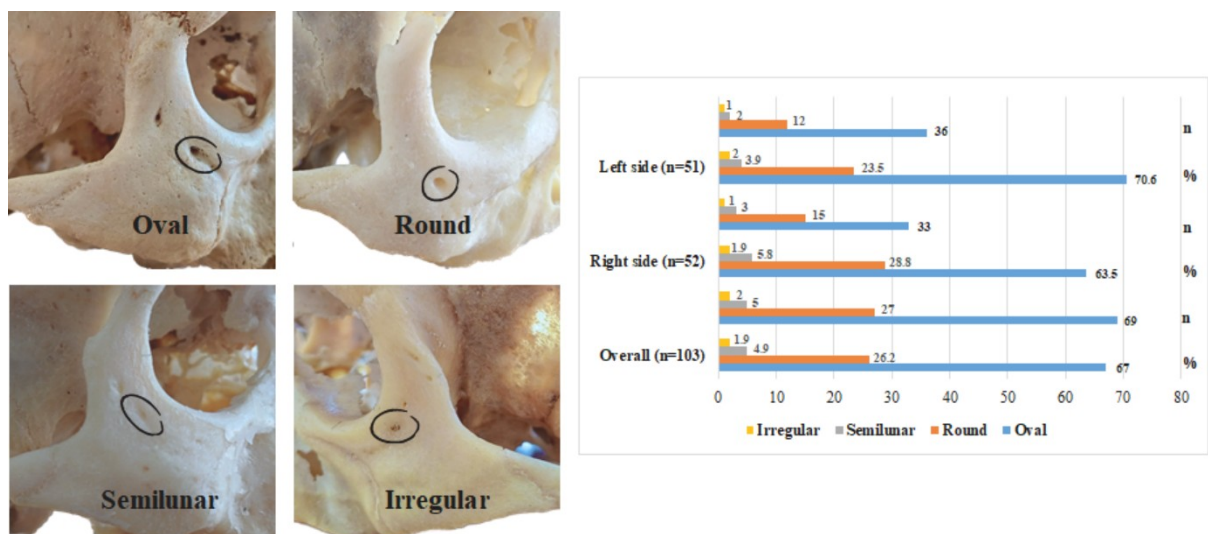
**Figure 3.** The relative position of the mZFF to the ZP is illustrated using a clock face representation. ZFF — zygomaticofacial foramen; ZP — zygomatic prominence.



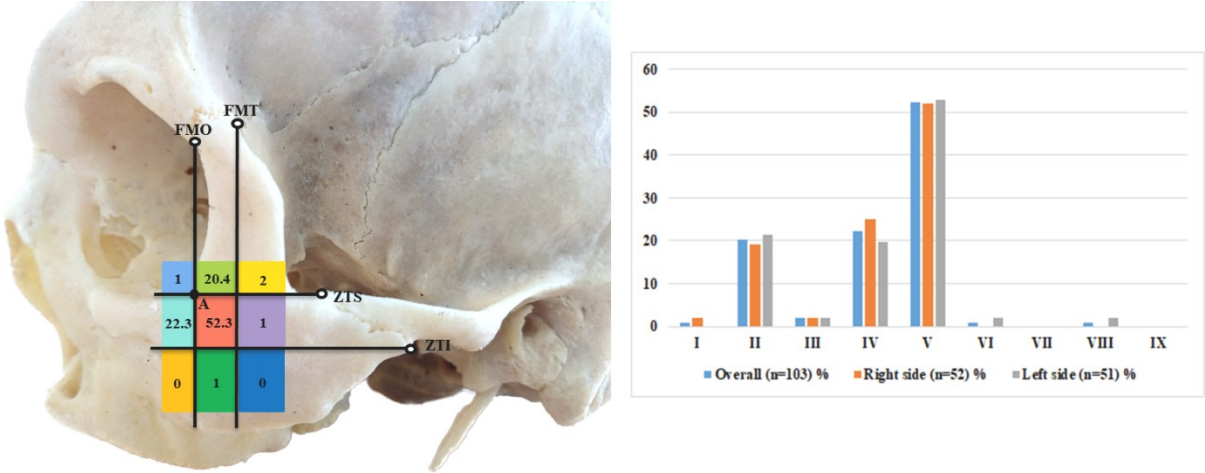
**Figure 4.** The number of identified mZFF (marked by black arrowheads).



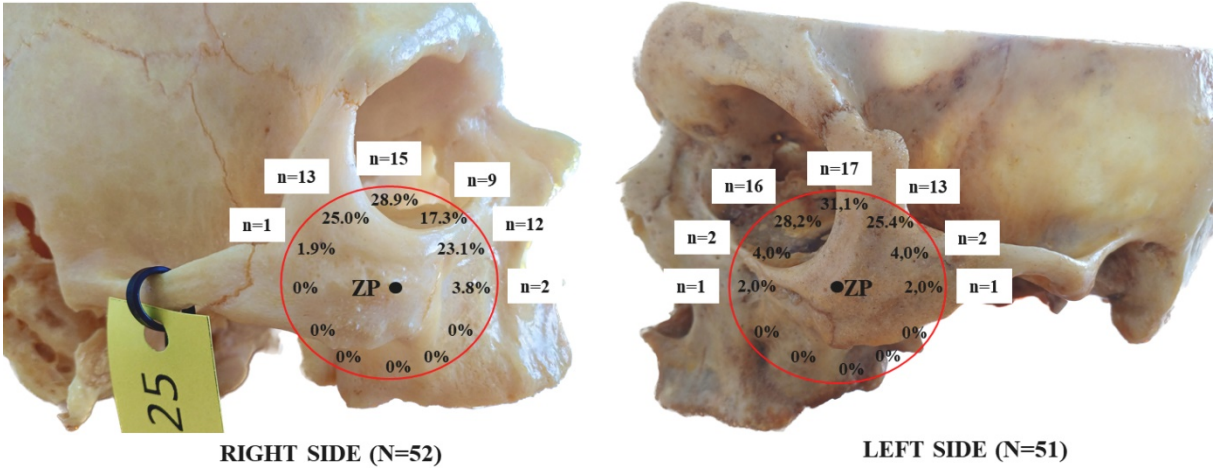
**Figure 5.** The statistical distribution of the mZFF diameters. The upper graph depicts the TD (mm), and the lower graph represents the VD (mm).



**Figure 6.** Various shapes of the mZFF (circled in black on the left) and their corresponding frequencies (number and percentage) are shown on the right.



**Figure 7.** The distribution of the mZFF across designated regions (I–IX) of the ZB in percentages. Point A refers to the intersection of the superior horizontal and anterior vertical lines on the lateral surface of the ZB. Notably, the majority of foramina are located in regions II, IV, and V, concentrated near point A.



**Figure 8.** The distribution of the mZFF location relative to the ZP is depicted using a clock face representation. The frequency of foramen position is presented as both percentages and numbers.